

# Retrograde Transcarotid Revascularization for Symptomatic Proximal Common Carotid Stenosis

BY PETER ROSSI, MD, FACS, FSVS

Symptomatic common carotid artery and/or innominate artery disease is uncommon. Management options for proximal common carotid stenosis include open surgical reconstruction, transfemoral carotid artery stenting, or retrograde transcarotid revascularization (R-TCAR). Origin common carotid or innominate lesions can present procedural difficulties: engaging the lesion can itself be challenging, and distal embolic protection is extremely difficult. R-TCAR can provide a novel approach to these challenging lesions while providing excellent embolic protection with flow diversion to the femoral vein.

## CASE REPORT

A 65-year-old man presented to a referring institution with repeated episodes of left-sided amaurosis fugax. Carotid duplex ultrasound revealed tardus parvus waveforms throughout the entire cervical carotid system. Subsequent CTA revealed high-grade common carotid artery stenosis starting 1.5 cm from the aortic arch (Figure 1). Dual antiplatelet therapy was initiated with clopidogrel and aspirin, along with atorvastatin, and recommendation was made for R-TCAR.

Under general anesthesia, the distal left common carotid artery was exposed through a small longitudinal incision. R-TCAR with distal common carotid artery

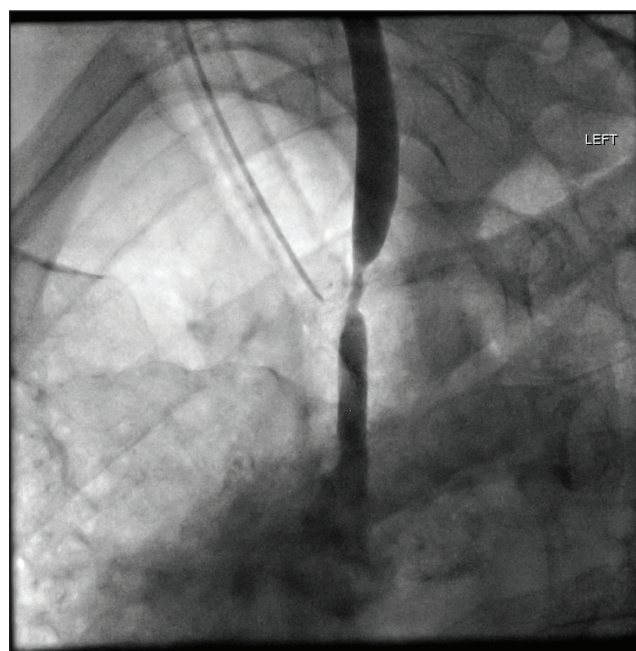


Figure 1. Initial angiogram prior to treatment.

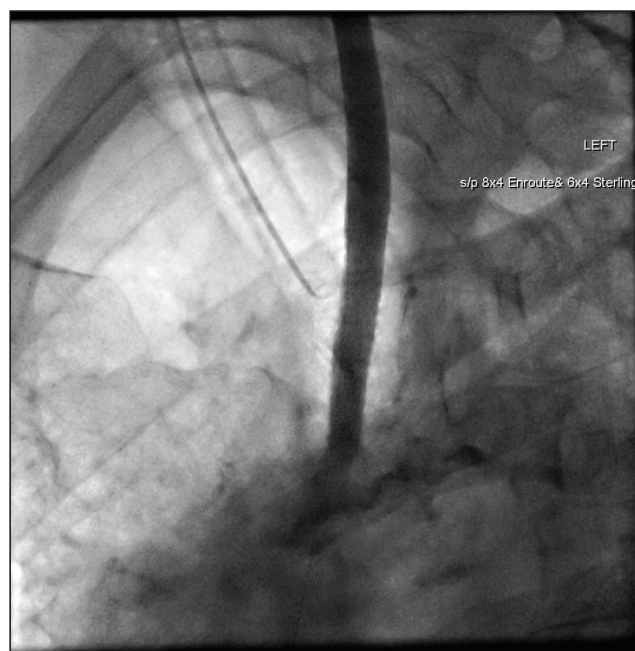


Figure 2. Angiogram immediately after treatment.

retrograde access was performed utilizing flow diversion to the right femoral vein. An 8- X 40-mm ENROUTE® Transcarotid Stent (Silk Road Medical) was placed. The R-TCAR procedure was uncomplicated, with a total flow diversion time of 9 minutes and total procedure time of 68 minutes, which was well tolerated with no neurological events (Figure 2). The patient was discharged to home the following day with no perioperative complications. At 1-year follow-up, he remained asymptomatic and his stent was widely patent with no evidence of stenosis.

## DISCUSSION

Symptomatic severe (> 70%) internal carotid artery stenosis is associated with an ipsilateral stroke rate of up to 26% over 2 years following the initial event.<sup>1</sup> Carotid endarterectomy (CEA) is the gold standard for correction of carotid artery stenosis in appropriately selected symptomatic patients, but may be associated with a periprocedural stroke and death rate of up to 5.8%.<sup>1</sup> Patients with cardiac comorbidities may have increased perioperative cardiopulmonary risk with carotid endarterectomy. Corresponding data are not available for proximal carotid and innominate lesions, with most literature being limited to case reports and small case series. In our practice, surgical and endovascular management of these lesions is offered almost exclusively to symptomatic patients.

Transfemoral carotid angioplasty and stenting (CAS) with an embolic protection device (EPD) is currently approved by the Centers for Medicare and Medicaid Services (CMS) only for symptomatic patients, as several well-publicized studies have shown increased risk of perioperative stroke with CAS compared to CEA. One hypothesis for the increased stroke risk is manipulation of the sheath and catheter system in the aortic arch, along with the need to cross the carotid lesion with a wire prior to deployment of the EPD. Over the last few years, antegrade transcarotid artery revascularization (TCAR) has emerged as a promising technique for treatment of high-risk patients with carotid artery disease. TCAR with neuroprotection using the ENROUTE® Transcarotid

Neuroprotection System (Silk Road Medical) for flow reversal to the femoral vein is the only CMS-approved technique for CAS in asymptomatic, high-risk patients. The ROADSTER 1 trial demonstrated an ipsilateral stroke rate with this technique of 1.3%, which compares favorably with historical CEA stroke rates.<sup>2</sup>

Retrograde carotid stenting has been shown to be safe when combined with CEA in selected cases.<sup>3</sup> While transfemoral stenting may be feasible for these proximal lesions, a recent meta-analysis showed a 30-day stroke rate of up to 3%, with only half of the patients in the overall study being symptomatic.<sup>4</sup> To date, no large prospective trial data validate this concept for stroke prevention in asymptomatic patients.


To our knowledge, this is the first reported case of R-TCAR for a symptomatic proximal lesion. Further study is necessary to determine the safety and efficacy of this technique, and we do not recommend its use for asymptomatic patients whose stroke rate with good medical management is not clearly defined. ■

1. North American Symptomatic Carotid Endarterectomy Trial Collaborators; Barnett HJM, Taylor DW, Haynes RB, et al. Beneficial effect of carotid endarterectomy in symptomatic patients with high-grade carotid stenosis. *N Engl J Med*. 1991;325:445-453.

2. Malas MB, Dakour-Arifi H, Wang GJ, et al. Transcarotid artery revascularization versus transfemoral carotid artery stenting in the Society for Vascular Surgery Vascular Quality Initiative. *J Vasc Surg*. 2019;69:92-103.e2.

3. Bozzay J, Broce M, Mousa AY. Hybrid treatment of extracranial carotid artery disease. *Vasc Endovascular Surg*. 2017;51:373-376.

4. Zhang X, Ma H, Li L, et al. A meta-analysis of transfemoral endovascular treatment of common carotid artery lesions. *World Neurosurg*. 2019;123:89-94.



### Peter Rossi, MD, FACS, FSVS

Chief, Division of Vascular and Endovascular Surgery

Associate Professor of Surgery, Radiology and Orthopedic Surgery

Associate Director, Heart and Vascular Service Line

Medical College of Wisconsin  
Milwaukee, Wisconsin

prossi@mcw.edu

*Disclosures: Proctoring and consulting fees from Silk Road Medical.*